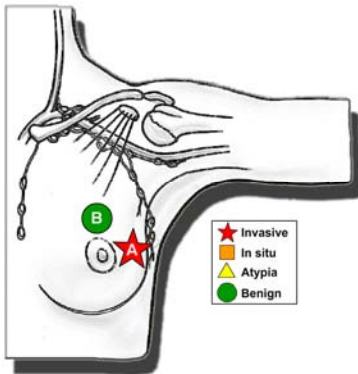


Patient Information		GEISINGER MEDICAL LABORATORIES
Name: TEST, BREAST DOB (AGE) Sex: 7/27/1963 (46) F MRN (Client MRN):		
		Billing #: Order #:
Client Information	Specimen Information	
Location: Shamokin Hospital Copy To: Outside Client.:	Collected Date: 8/3/2009 Accession #: S09-366 Accession Date: 8/3/2009 Client Case #: Reported Date: 8/4/2009 Report Type: Final Report Submitting: - Dr Testing	

Procedures/Addenda Present

SURGICAL PATHOLOGY DIAGNOSIS

Electronically Signed Out: Jeffrey W Prichard, D.O. - GMC Lab



(A) Left breast at 3:00, core biopsy:

- Invasive duct carcinoma, NOS, intermediate grade
- Invasive tumor is 1.2 cm in greatest dimension in the biopsy

(B) Left breast at 12:00, core biopsy:

- Benign atrophic fibrous breast tissue

Clinical History

Left breast, ?malignancy vs. post-op changes. Patient had left breast cancer six years ago.

Synoptic Data

MACROSCOPIC

SPECIMEN TYPE: Percutaneous core biopsy
 TUMOR SITE: Left breast

MICROSCOPIC

HISTOLOGIC TYPE: Invasive ductal carcinoma
 HISTOLOGIC GRADE: Nottingham Histologic Score: Tubule formation: Minimal <10% (score = 3)
 Nuclear Pleomorphism: Moderate increase in size, etc. (score = 2)
 Mitotic count for a 40x objective: 0 - 5 mitoses per 10 HPF (score = 1)
 Total score: Grade II: 6 - 7 points

MICROCALCIFICATIONS: Not identified

ADDITIONAL STUDIES: Immunoperoxidase stains for estrogen and progesterone receptors have been ordered; the results will be reported in an addendum.
 The Herceptest by immunoperoxidase has been ordered; the results will be reported in an addendum.

Photographic images and diagrams represent key findings in this case; they are not intended to replace a complete review of the final diagnostic report.

The following statement applies to Flow Cytometry, Immunohistochemistry, Molecular Genetics, Immunofluorescence, and In situ Hybridization Assays: This test was developed and its performance characteristics determined by Geisinger Medical Laboratories. It has not been cleared or approved by the U.S. Food and Drug Administration. The FDA has determined that such clearance or approval is not necessary. This test is used for clinical purposes. It should not be regarded as investigational or for research.

Gross Description

Grossed:

Grossed By: Sara J Scullin

Gross Status:

A: Received in formalin labeled left breast US cores, 3 o'clock, placed in formalin at 11:10 AM on 8/3/09, are multiple pink-yellow, fibrofatty cores of tissue measuring from 0.1 cm. to 1.0 cm. Wrapped in lens paper and entirely submitted in cassette A1 marked LEVELS X3.

B: Received in formalin labeled left breast US cores, 12 o'clock, placed in formalin at 11:20 AM on 8/3/09, are three pink- yellow, fibrofatty cores of tissue measuring 0.3 and 0.5 cm. Wrapped in lens paper and entirely submitted in cassette B1 marked LEVELS X3. SS

Microscopic Findings

Microscopic examination of the biopsy at 3 o'clock shows infiltrating epithelial cells without prominent luminal formation with small nested architecture and numerous signet ring forms. Positive immunohistochemical staining of the invasive tumor with e-cadherin confirms the ductal differentiation. Tumor nuclei are 2-3 larger than normal duct epithelial nuclei and containing nucleoli. Mitotic figures are rare (<1/10hpf). There is no evidence of lymphovascular invasion. Immunohistochemical stain for p63 demonstrates a lack of myoepithelial cells around the invasive tumor nests. The largest dimension of invasive tumor in the biopsy is 1.2 cm. There is no evidence of calcifications.

Microscopic examination of the biopsy at 12 o'clock shows densely fibrous cores with few residual atrophic ducts. There is no evidence of calcifications, atypia or malignancy.

Flow Cytometry Procedure

Ordered:

Status: P

Reported Date:

Flow Cytometry Diagnosis

Electronically Signed Out: Jeffrey W Prichard, D.O. - GMC Lab

Immunohistochemical pathologic evaluation of this invasive tumor performed on 10% neutral buffered formalin fixed paraffin embedded tissue for hormone receptor protein expression with Dako 1D5 and PgR636 clones and quantitative image analysis shows:

Estrogen Receptor (ER) protein expression is NEGATIVE (0% nuclear positivity)

Progesterone Receptor (PR) protein expression is NEGATIVE (0% nuclear positivity)

Fixation: This specimen meets CAP/ASCO guidelines for fixation (6-48 hours in formalin)

COMMENT: Negative hormone receptor status in invasive breast cancer tends to be linked to poorer survival and unfavorable response to endocrine-based therapy.

Reference: Fisher ER, Anderson S, Dean S, Dabbs D, Fisher B, Siderits R, Prichard J, Pereira T, Geyer C, Wolmark N. Solving the dilemma of the immunohistochemical and other methods used for scoring estrogen receptor and progesterone receptor in patients with invasive breast carcinoma. Cancer. 2005 Jan 1;103(1):164-73.

Specimen type: A: Breast, core Biopsy at 1:00

B: Breast, core Biopsy at 12:00

Supporting Data

Flow Cytometry Diagnosis

Electronically Signed Out: Jeffrey W Prichard, D.O. - GMC Lab

Immunohistochemical pathologic evaluation of this invasive tumor performed on 10% neutral buffered formalin fixed paraffin embedded tissue in with Dako HercepTest antibody kit and quantitative image analysis of oncoprotein expression shows:

Her-2/neu oncoprotein expression is EQUIVOCAL (2.0 membranous intensity) to be confirmed by in-situ hybridization with results to follow

Reference ranges (membrane staining intensity):

< 1.6 not overexpressed
1.6 to 2.5 equivocal (to be confirmed by in-situ hybridization)
> 2.5 overexpressed

Fixation: This specimen meets CAP/ASCO guidelines for fixation (6-48 hours in formalin)

References: American Society of Clinical Oncology/College of American Pathologists guideline recommendations for human epidermal growth factor receptor 2 testing in breast cancer. J Clin Oncol. 2007 Jan 1;25(1):118-45.

Specimen type: A: Breast, core Biopsy at 1:00

B: Breast, core Biopsy at 12:00

Supporting Data

Flow Cytometry Diagnosis

Electronically Signed Out: Jeffrey W Prichard, D.O. - GMC Lab

HER-2/neu GENE STATUS BY FISH:

Fixation: This specimen meets CAP/ASCO guidelines for fixation (6-48 hours in formalin)

Result: **AMPLIFIED**

HER-2/CEP 17 ratio	2.98
Her-2/neu average copies/cell	10.2
CEP 17 average copies/cell	3.42

The Molecular Diagnostics Laboratory uses the PathVysion HER-2/neu DNA probe kit (Vysis, Inc) for the detection of HER-2/neu gene amplification in breast biopsied tissue. CAP/ASCO guidelines include the following recommendations for specimens submitted for HER2/neu testing by Fluorescence In Situ Hybridization (FISH). The tissue must be paraffin-embedded and fixed in 10% neutral buffered formalin for 6 to 48 hours. False negative results may occur when tissues are fixed for more than 48 hours. Therefore, the results from specimens that are fixed for unknown or prolonged periods must be evaluated judiciously. Target areas of invasive tumor are selected from corresponding H&E stained sections. Specimens are hybridized concurrently to DNA probes specific for the HER-2/neu gene locus and for the alpha satellite DNA sequence at the centromeric region of chromosome 17 (CEP 17 control). HER-2/neu and CEP 17 signals are visualized by epifluorescence microscopy and the ratio of HER-2/neu to CEP 17 copy number in 60 nuclei is used to discriminate between chromosome 17 aneusomy and true HER-2/neu gene amplification. Non-tumor cells in each biopsied specimen are used as normal HER2 controls. Commercially available specimens with HER2 to CEP17 ratios in the equivocal range are included in every assay. Each specimen is evaluated by at least two observers including a pathologist. If fewer than 60 invasive tumor cells are available, the specimen is classified as "inadequate for sample evaluation". According to current CAP/ASCO guidelines, a positive HER2 result is a FISH ratio (HER2 gene signals to chromosome 17 signals) of more than 2.2, and a negative result is a FISH ratio of less than 1.8. Equivocal results between 1.8 and 2.2 may require immunohistochemical results to make a final determination.

Sensitivity and specificity of this FDA approved test are 96.5% and 100%, respectively. The results of this test should be interpreted within the context of clinical presentation and additional pathologic information. The Molecular Diagnostics Laboratory has validated the analytical performance characteristics of this test.

Reference:

American Society of Clinical Oncology/College of American Pathologists guideline recommendations for human epidermal growth factor receptor 2 testing in breast cancer. J Clin Oncol. 2007 Jan 1;25(1):118-45.

Specimen type: A: Breast, core Biopsy at 1:00
B: Breast, core Biopsy at 12:00

Supporting Data

Procedure Data

ER/PR Receptors

Date Ordered: 8/4/2009 Status : Signed Out
Date Completed: 8/4/2009 Date Reported: 8/6/2009

Impression:

Immunohistochemical pathologic evaluation of this invasive tumor performed on 10% neutral buffered formalin fixed paraffin embedded tissue for hormone receptor protein expression with Dako 1D5 and PgR636 clones and quantitative image analysis shows:

Estrogen Receptor (ER) protein expression is NEGATIVE (0% nuclear positivity)
Progesterone Receptor (PR) protein expression is NEGATIVE (0% nuclear positivity)

Fixation: This specimen meets CAP/ASCO guidelines for fixation (6-48 hours in formalin)

COMMENT: Negative hormone receptor status in invasive breast cancer tends to be linked to poorer survival and unfavorable response to endocrine-based therapy.

Reference: Fisher ER, Anderson S, Dean S, Dabbs D, Fisher B, Siderits R, Prichard J, Pereira T, Geyer C, Wolmark N. Solving the dilemma of the immunohistochemical and other methods used for scoring estrogen receptor and progesterone receptor in patients with invasive breast carcinoma. Cancer. 2005 Jan 1;103(1):164-73.

JWP Electronically Signed Out:

Her-2-Neu

Date Ordered: 8/4/2009 Status : Signed Out
Date Completed: 8/4/2009 Date Reported: 8/7/2009

Impression:

Immunohistochemical pathologic evaluation of this invasive tumor performed on 10% neutral buffered formalin fixed paraffin embedded tissue in with Dako HercepTest antibody kit and quantitative image analysis of oncoprotein expression shows:

